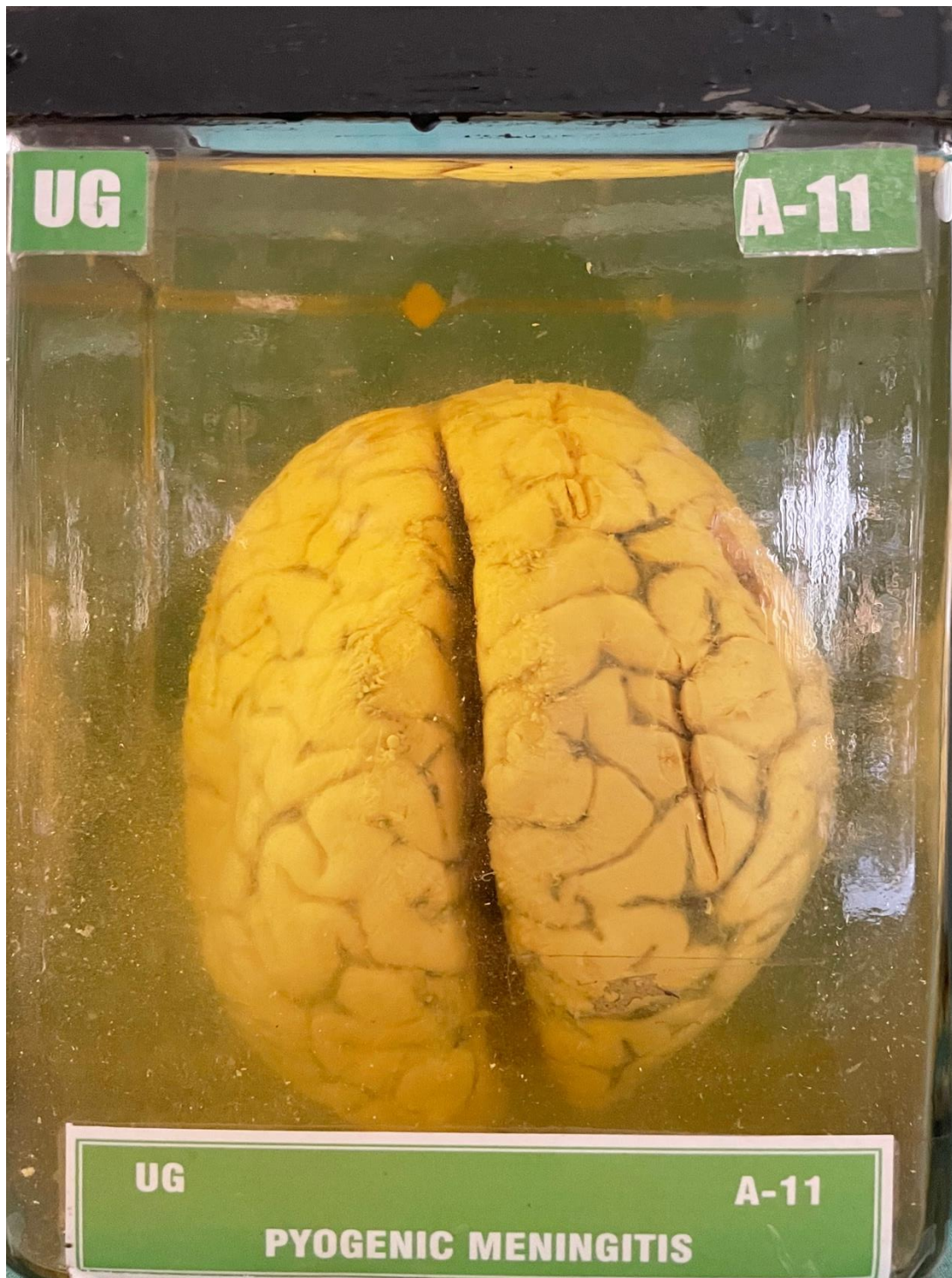


A11 – PYOGENIC MENINGITIS



HISTORY:- A man, aged 27 years, came to the Hospital with ~~recent~~ history of abdominal pain and vomiting. He was being treated as a case of gastroenteritis. On detailed examination, neck rigidity was noted. He had bilateral chronic suppurative otitis media. By the time antibiotics were introduced. Patient expired. Post mortem examination revealed pyogenic meningitis.

MACROSCOPY:- Specimen of brain, shows markedly congested vessels. Along the vessels and in the sulci, yellowish opaque exudate is seen. The exudate is more at the base of brain.

MICROSCOPY:- Shows thick purulent exudate in the meninges.

Impression: → *Pyogenic meningitis*

BGM:15/5/80.