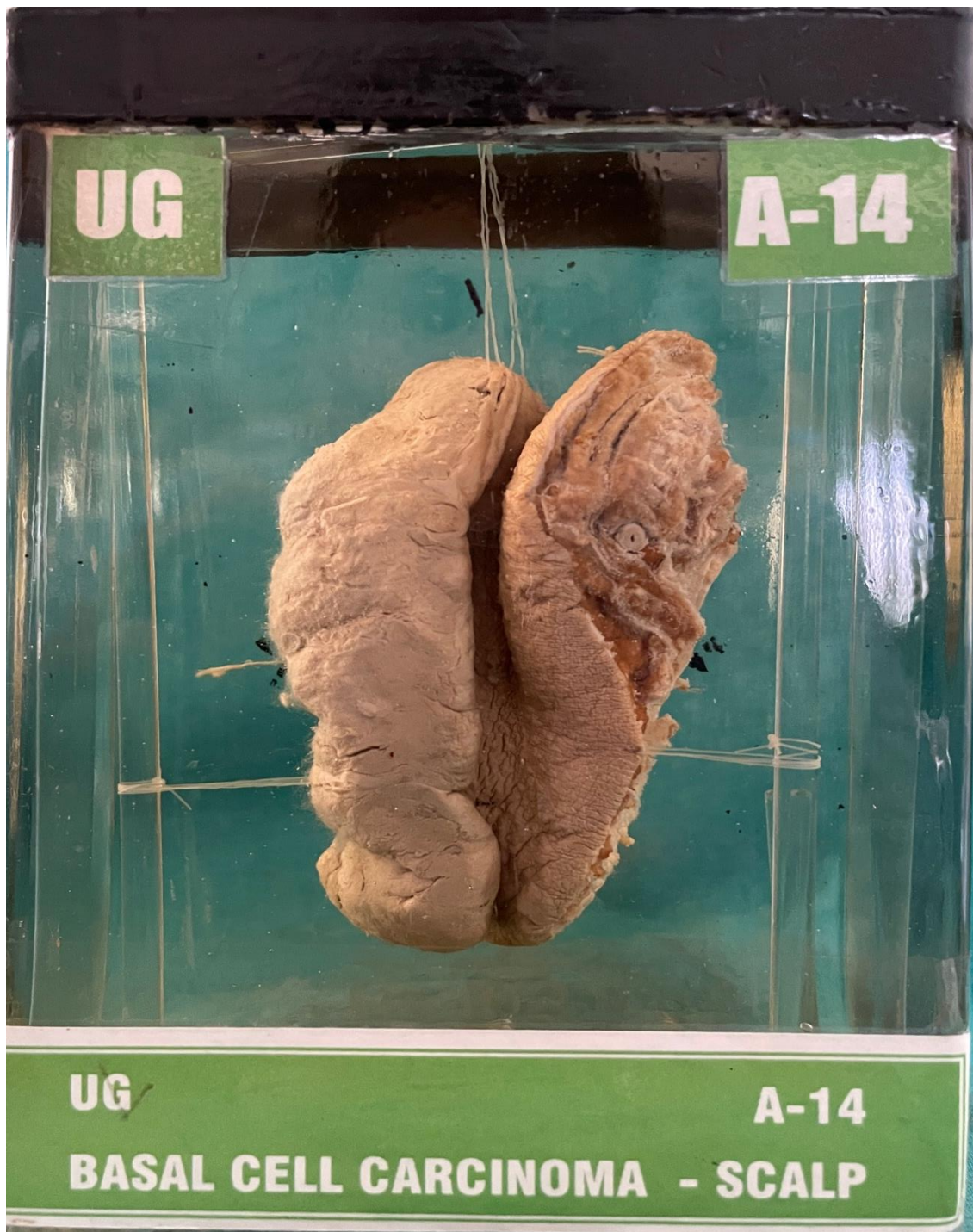


A14 – BASAL CELL CARCINOMA-SCALP



HISTORY:- A female patient aged 50 years presented with an ulcerated growth on the lateral aspect of the scalp (in front of the ear lobule).

GROSS APPEARANCE:- Specimen consists of an ulcerated growth covered with skin only at the periphery. The surface is nodular. Cut section shows a growth comprised of greyish white tissue in lobular pattern. The growth has infiltrated the deeper layers.

MICROSCOPY:- Shows a neoplastic growth comprised of small oval cells having basophilic cytoplasm with a round nucleus. There are frequent abnormal mitotic figures. The cells are seen in nest of varying sizes and shapes. Many of the nests show irregular pseudopodia like projections in the surrounding area. The cell nests are lined with cubical cells with palisaded arrangement of nuclei.

DIAGNOSIS:- Basal cell carcinoma.