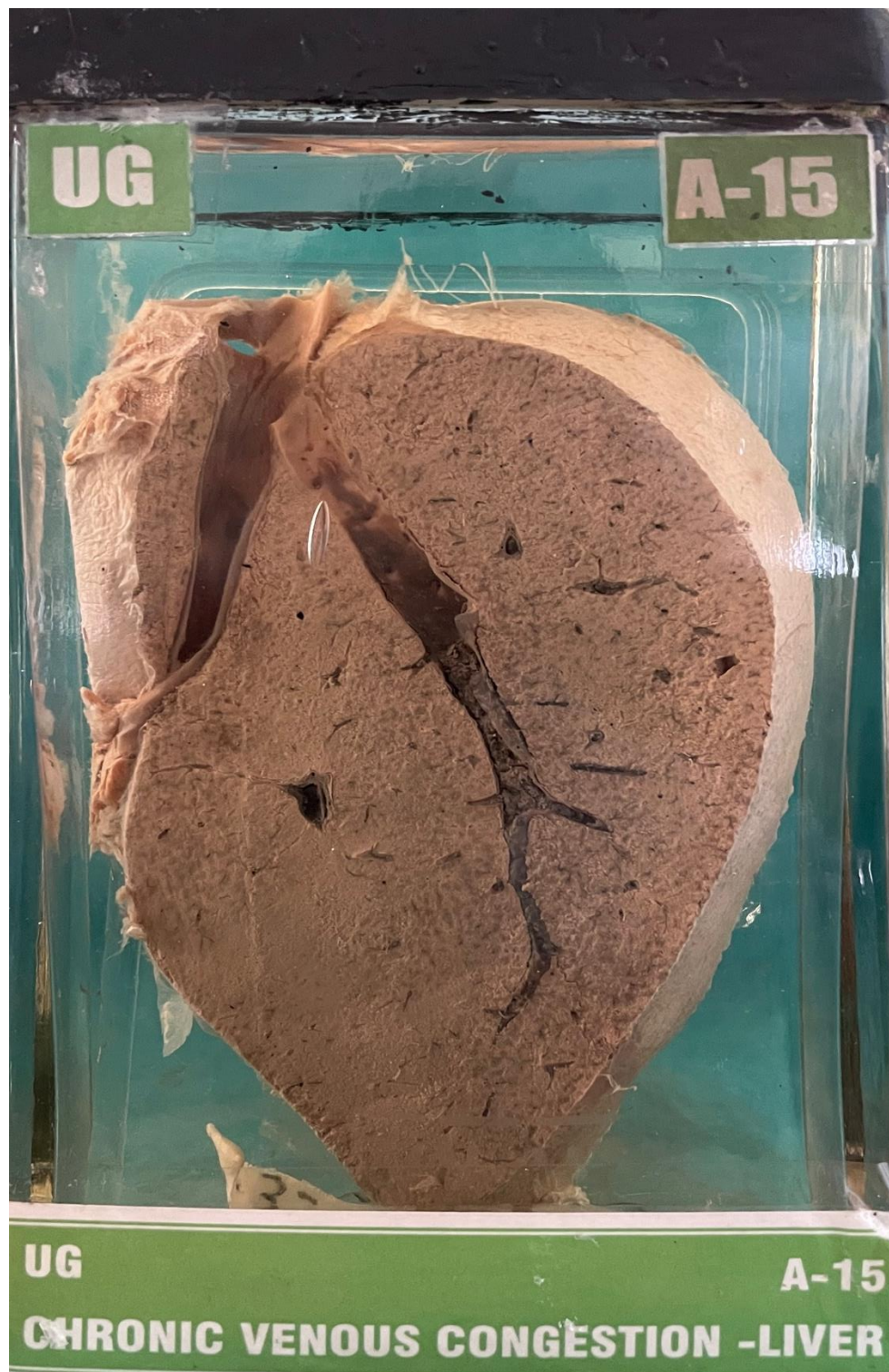


A15 – CHRONIC VENOUS CONGESTION-LIVER



C. V. C. LIVER

A Female patient of 35 years, was admitted in the Hospital with the complaints of Breathlessness, oedema of the face and feet for the past 3 years. Examination showed the signs of right heart failure. Patient expired. Autopsy conducted.


MACROSCOPY:-

- 1) Specimen of the Liver.
- 2) Moderately reduced in size.
- 3) Cut-surface shows engorged hepatic vein with blood.
- 4) Cut-section shows three prominent are
- 5) Blackish area congested, yellow area fatty infiltration and white that of normal tissue.

HISTOPATHOLOGY:-

Showed the picture of Chronic Venous Congestion.

P/37/71 1B-03

CHRONIC VENOUS CONGESTION LIVER

Engorged hepatic veins with Blood.

Alternating zone of dark & pale areas.
(Nutmeg appearance).