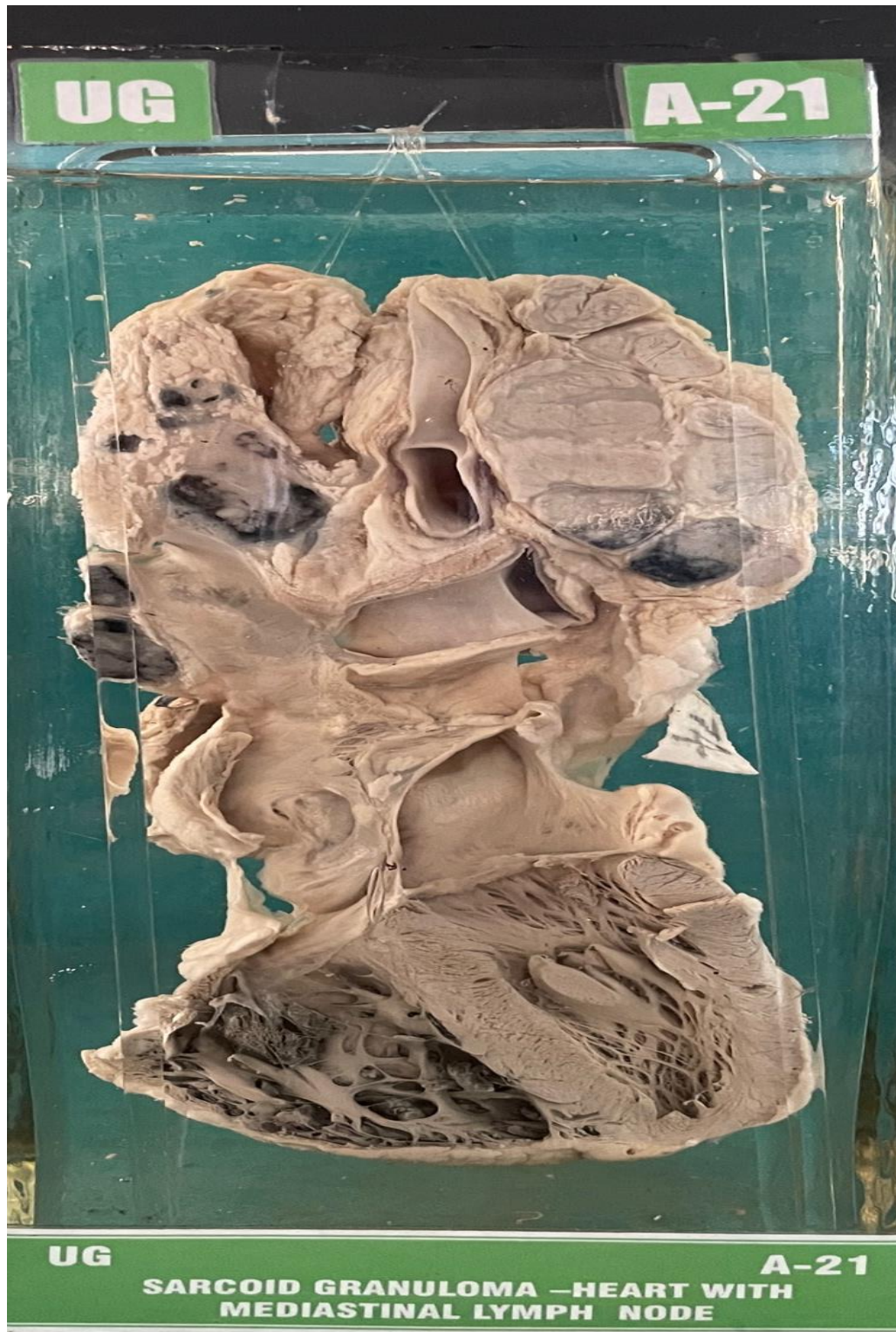


## A21 – SARCOID GRANULOMA-HEART WITH MEDIASTINAL LYMPHNODE



**UG**

**A-21**

**GROSS APPEARANCE:-** Specimen is comprised of heart, mediastinal enlarged lymph nodes and enlarged hilar lymph nodes. cut surface of lymph nodes (Mediastinal) has pink, homogenous appearance with two of them showing carbon pigment. The hilar lymph nodes (on your left) show carbon pigment alternating with pink homogenous areas.

**MICROSCOPY:-** Sarcoid granulomas completely replacing lymph node architecture are seen.