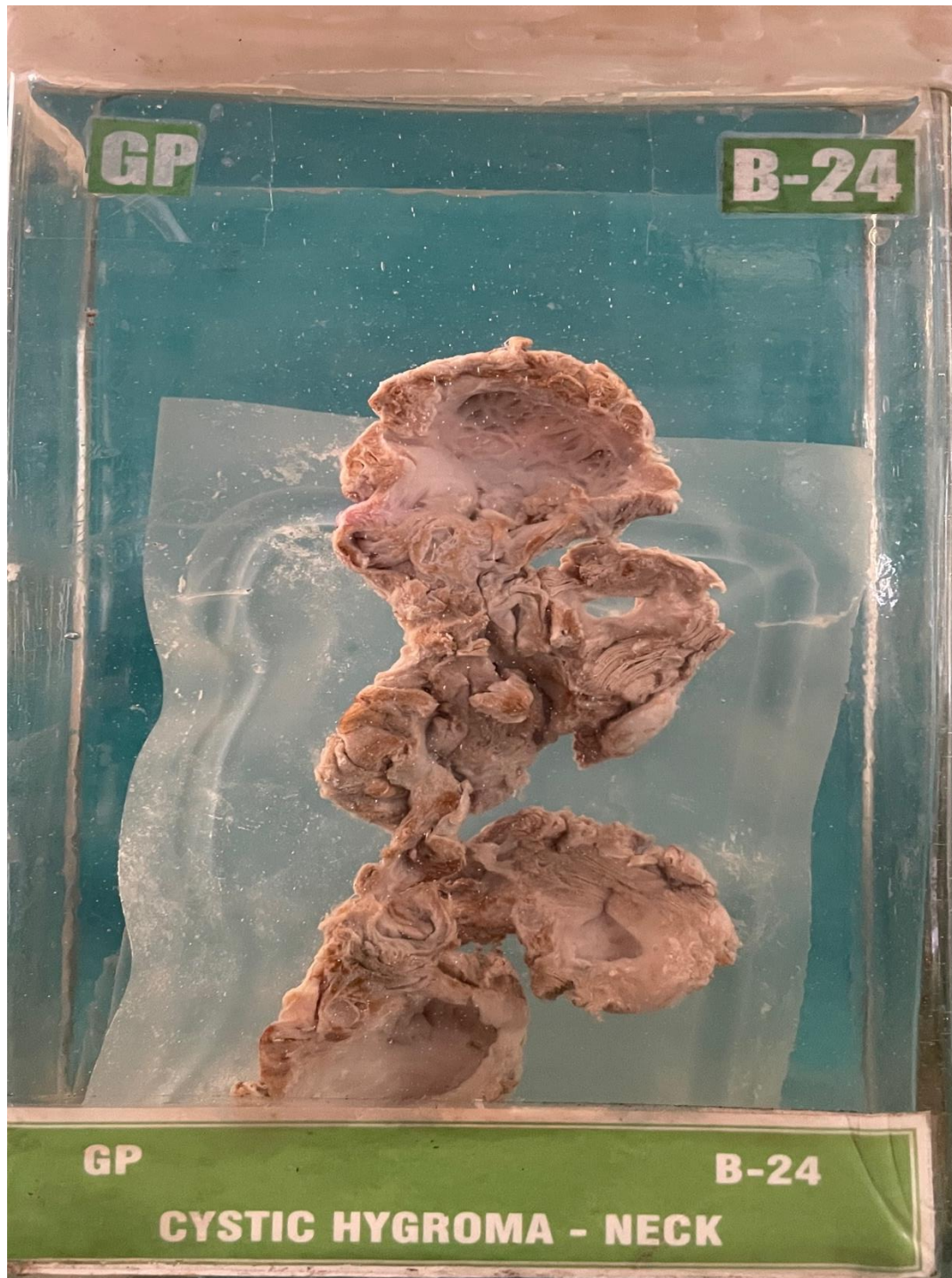


B24 – CYSTIC HYGROMA-NECK



HISTORY:- Eleven years old male had a swelling in the neck since Gradually increasing in size. Cystic in consistency.

HISTORY :- Cystic mass. Irregular in shape. Measured 8x5 cms. External is uneven. Shows fatty tissue at places. (pale in colour.) At places appears dark in colour.

Uniloculated. Cyst wall measures 2-3 cms in thickness.

MICROSCOPY:- Section studied shows benign growth. Shows multiple lined by endothelial cells. The cysts are of varying sizes & are filled with lymph. The stroma is comprised of collagenous. There is sparse round cell infiltration in the stroma.

Imp:- Cystic hygroma-Neck.