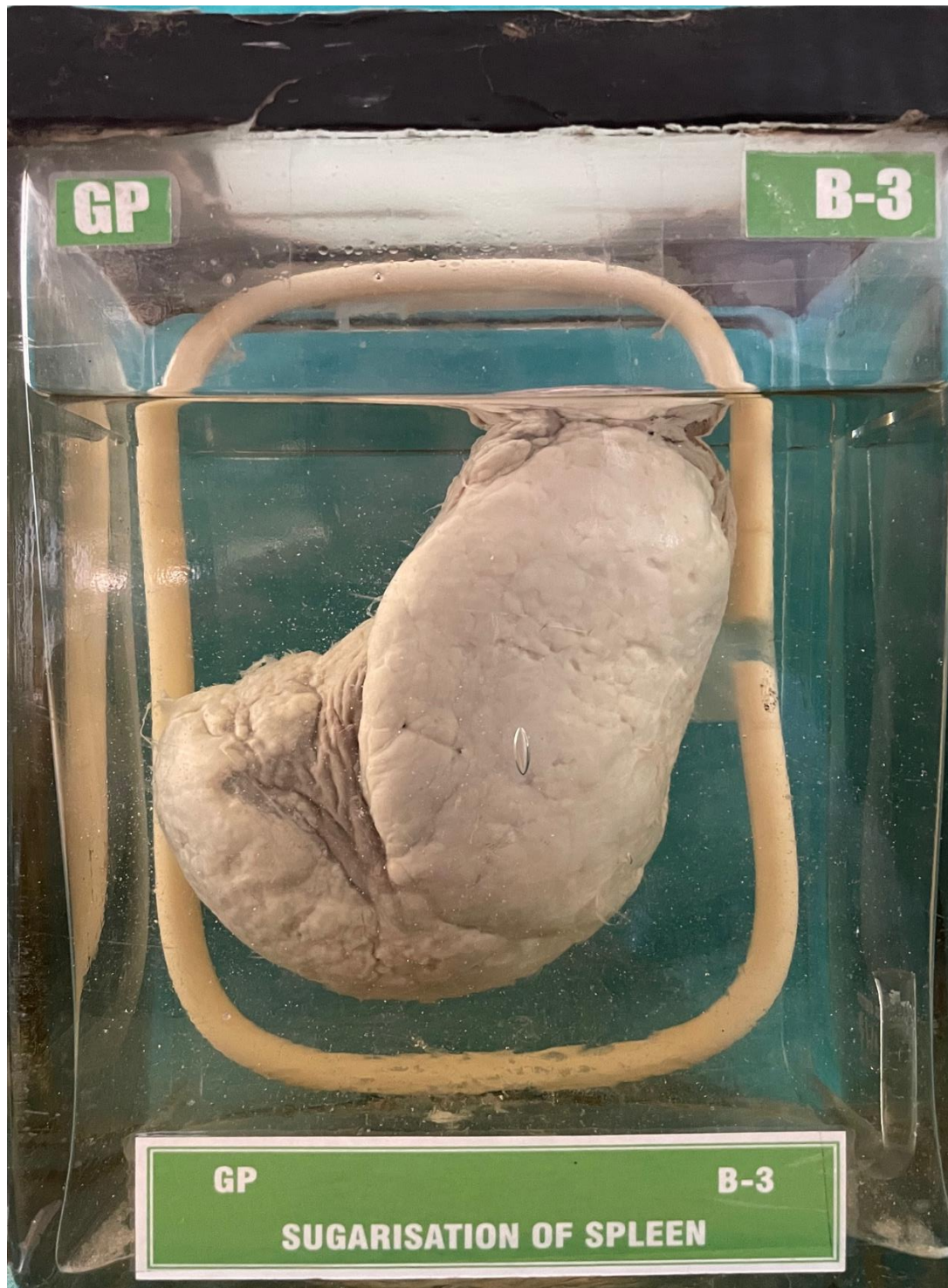


B3 – SUGARISATION OF SPLEEN



HISTORY:- A man aged 40 years died of hepatic coma due to post necrotic cirrhosis.

GROSS APPEARANCE:- Specimen of enlarged spleen shows a thick white plaque covering most of the upper surface of the spleen. Rest of the splenic capsule is also thickened and appears opaque.

DIAGNOSIS:- Sugarisation of spleen.