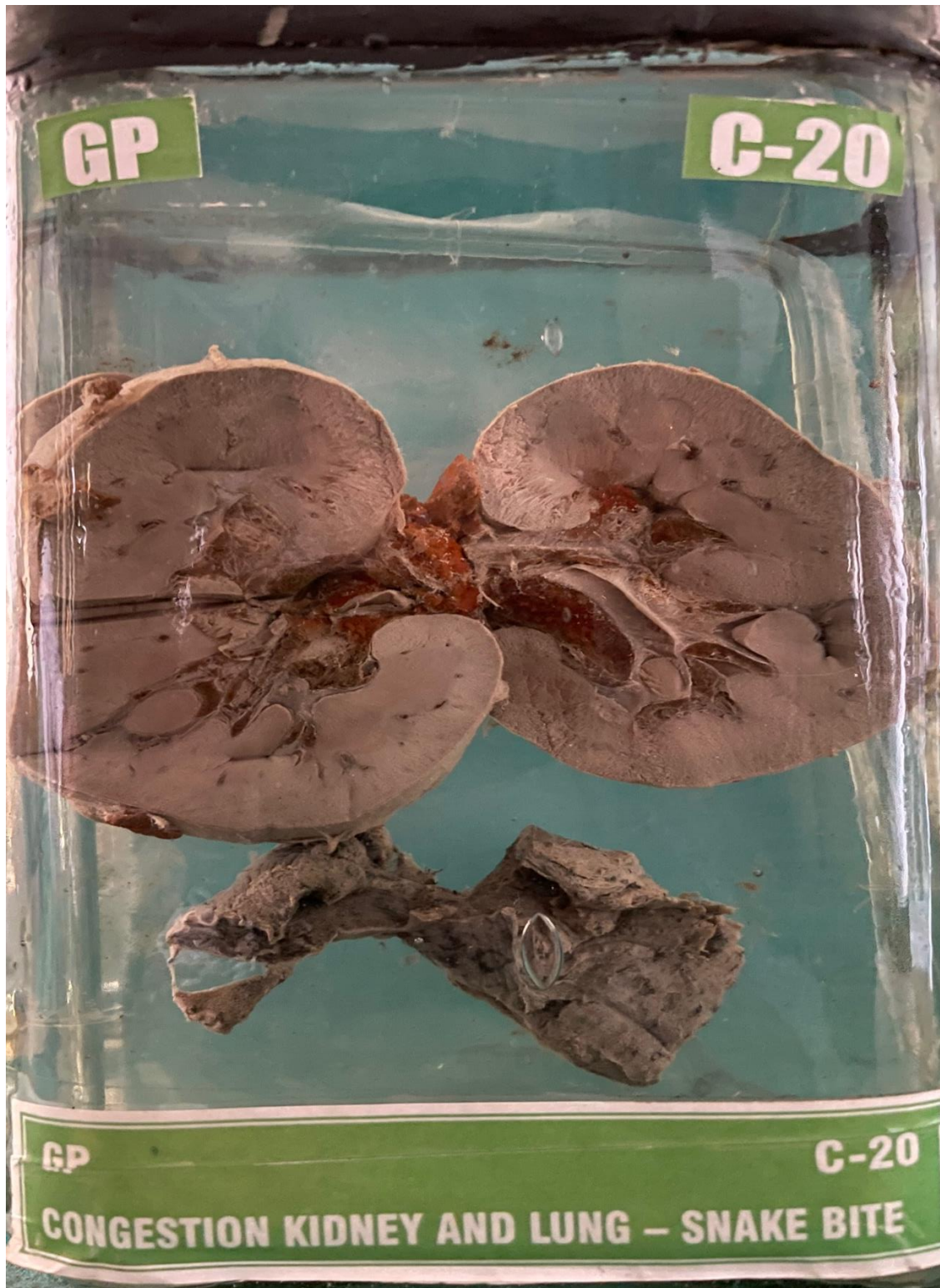


C20 – CONGESTION KIDNEY AND LUNG – SNAKE BITE



SNAKE BITE SPECIMENGross :

Specimen of kidney weighing 80 gms. Capsule can be stripped off easily. surface is smooth. Cut surface show thinned out cortex. There is increase in perinephric fat of fat.

Microscopy :

Section studied from the kidney show congestion.

Gross :

A piece of lung tissue. Measuring 6 x 2 cms. Pleura is transparent. Cut surface shows areas of haemorrhage.

Microscopy :

Section studied show congestion of lung.

Impression :

FEATURES ARE SUGGESTIVE OF

1. CONGESTION OF KIDNEY.
2. CONGESTION OF LUNG.