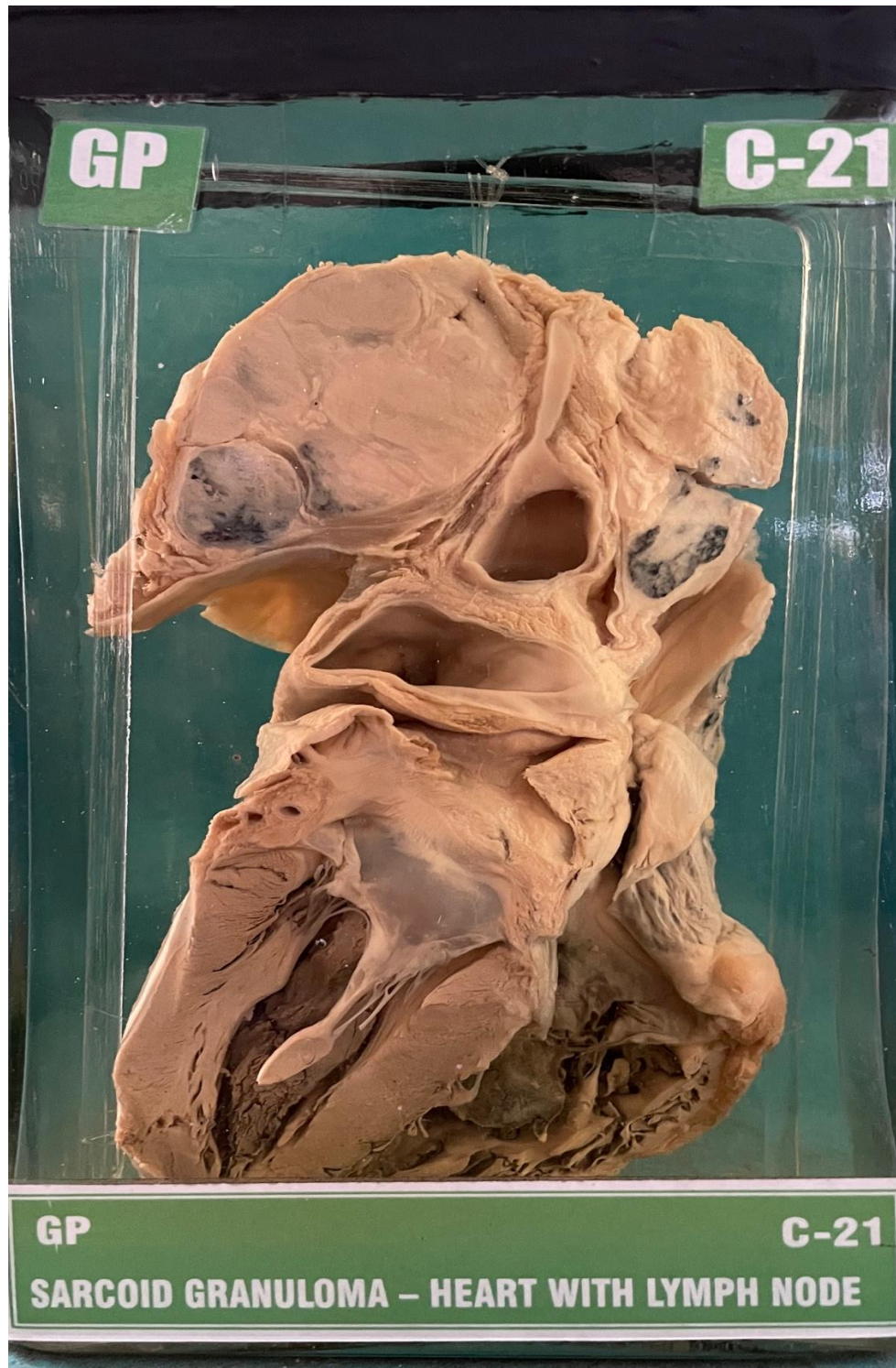


C21 – SARCOID GRANULOMA-HEART WITH LYMPHNODE



6. GROSS

Specimen of heart with mediastinal lymph nodes which are markedly increased in size and fused together. The cut surface of lymph nodes has pale pink colour.

(The lymph nodes on your left caused pressure on left main bronchus, leading to collapse of the lung.)