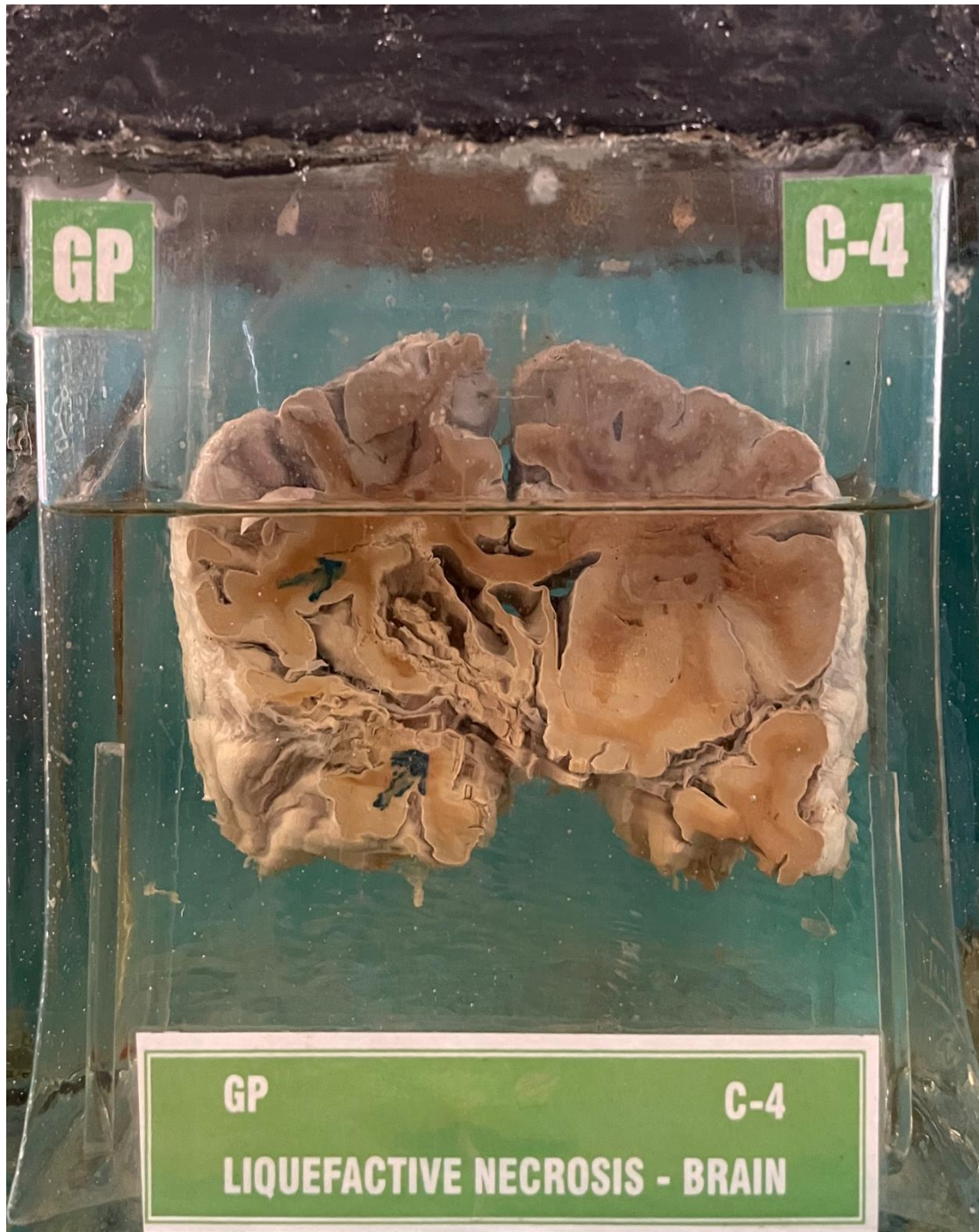


C4 – LIQUEFACTIVE NECROSIS-BRAIN



HISTORY:- An old man aged 70 years died of unconsciousness.

GROSS APPEARANCE:- Specimen of brain, meninges appear normal. The coronal section shows a cystic space just lateral to the left ventricle. The cavity is having a ragged lining and shows some opaque granular yellowish mass. The arrow at the bottom points to a sclerosed blood vessel.

MICROSCOPY:- Liquifactive necrosis brain.