D1 – GHONS' LESION-LUNG

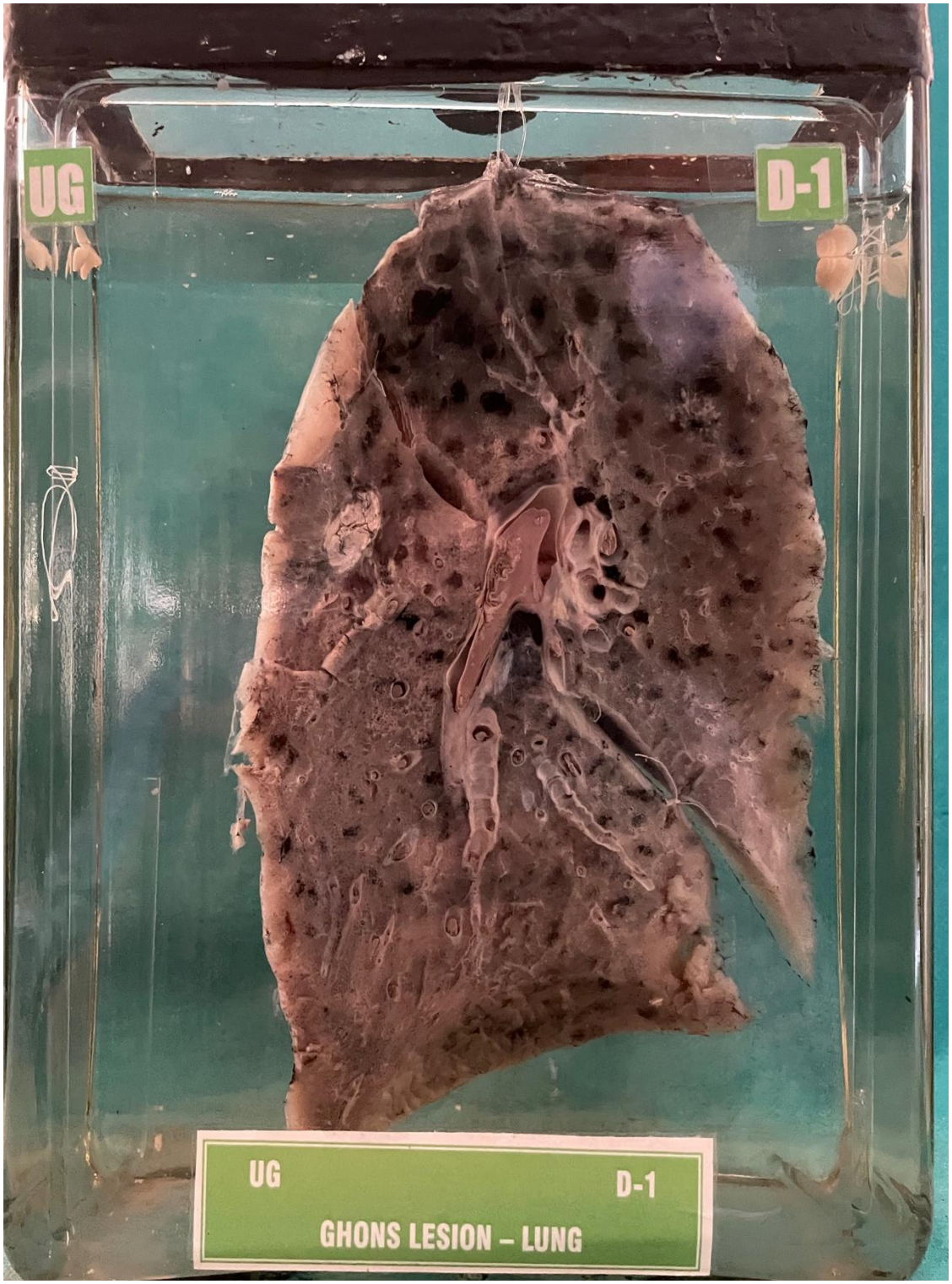

UG D-1

- Bisected specimen of left lung.
- The upper part of the lower lobe shows calcified well circumscribed oval area measuring 2 cms.
- The remaining lung parechyma appears normal.

IMP:- Ghon's lesion - upper lobe - left lung.