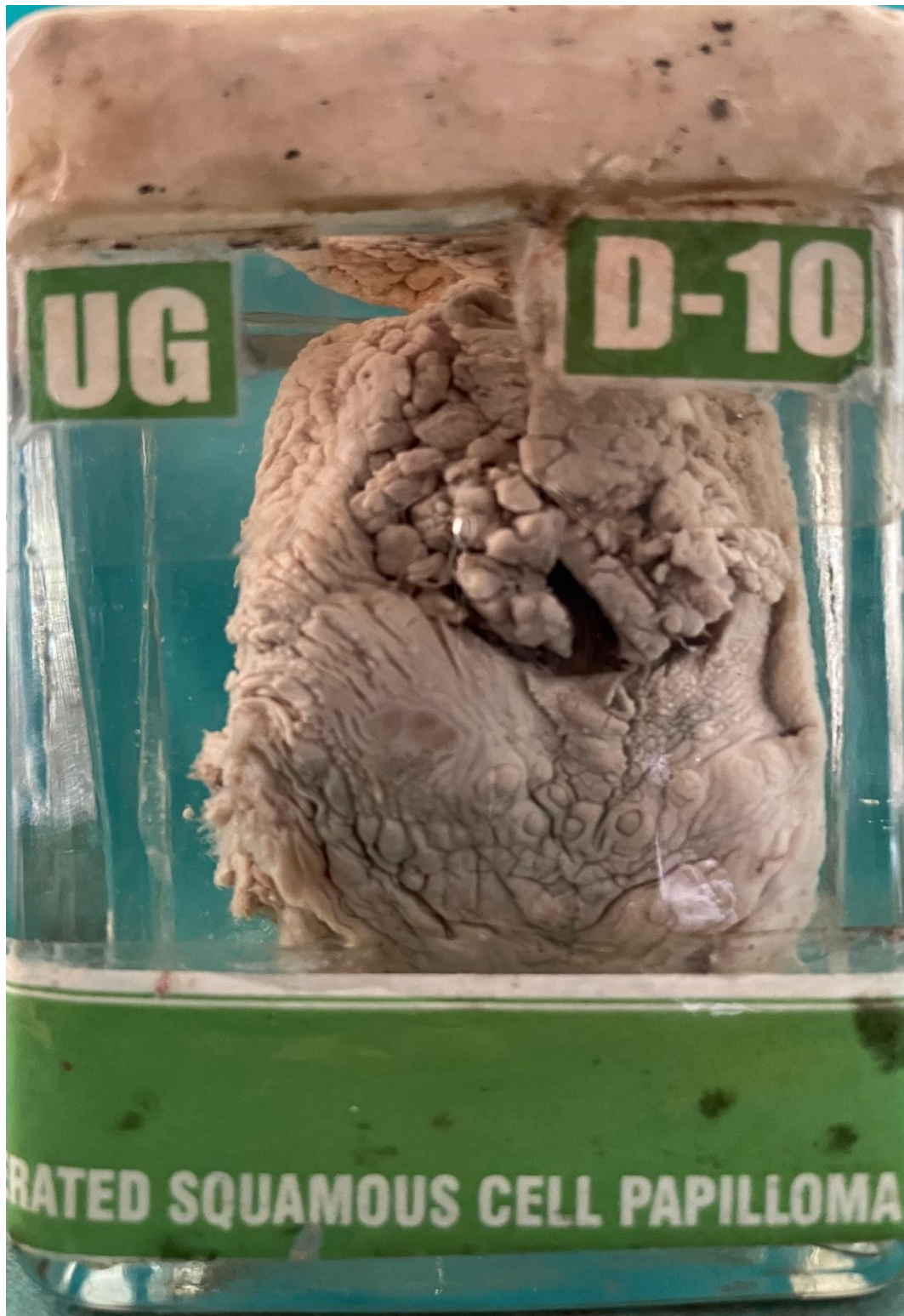


## D10 – SQUAMOUS CELL PAPILLOMA



1.13

**UG**

**D-10**

HISTORY:-

A male patient was admitted to District Hospital Belgaum, for the following complaints.

- Difficulty in swallowing since 5 months.

GROSS APPEARANCE:-

Specimen of tongue. There is a growth in central portion of tongue, measuring 4 x 2.5 cms. The growth is grayish pink and is cauliflower like. The remaining portion of the tongue appears normal.

MICROSCOPIC APPEARANCE:-

Sections studied show squamous epithelium and subepithelial tissue. The epithelium is thrown into the finger like projections. It is hyperkeratotic and ulcerated. The core of the papillary projections is a delicate fibrovascular tissue. A diffuse infiltration of inflammatory cells is seen in the subepithelial tissue. There is no evidence of malignancy.

IMPRESSION:-

Ulcerated squamous cell papilloma, tongue.

MVL/