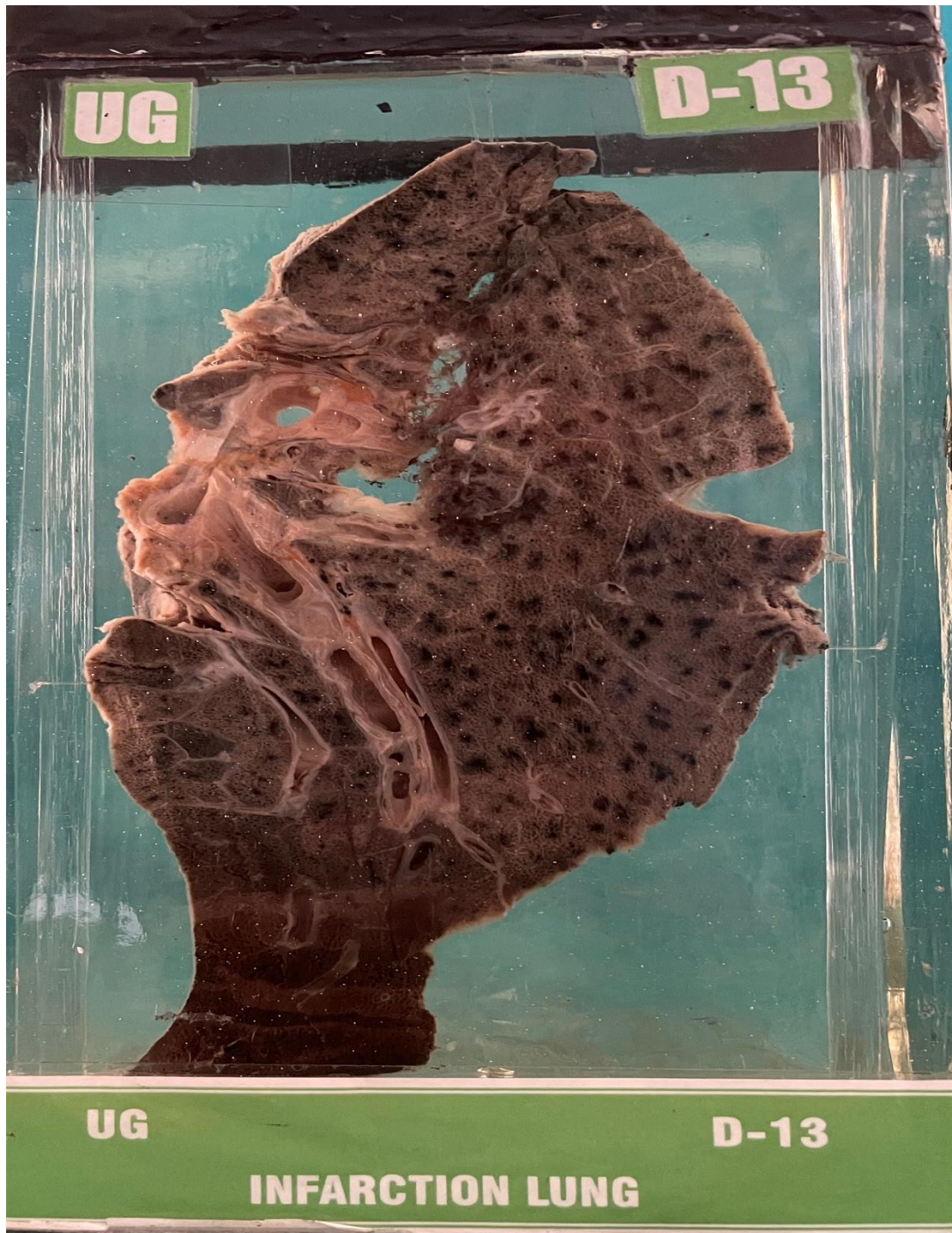


## D13 – INFARCTION LUNG



**HISTORY:-** A man aged 45 years suffering from cor pulmonale died of acute attack of acute attack of breathlessness and severe chest pain on right side.

**GROSS APPEARANCE:-** Specimen of lung very much enlarged in size, the pleural surface shows a layer of fibrinous deposition. The cut section shows a massive infarct of the lower lobe. Note the area of infarct with light black area and the zone of inflammation dark brown in colour. The arrow in the specimen points to the embolus in the large vessel of the lung.

**MICROSCOPY:-** Infarction lung.