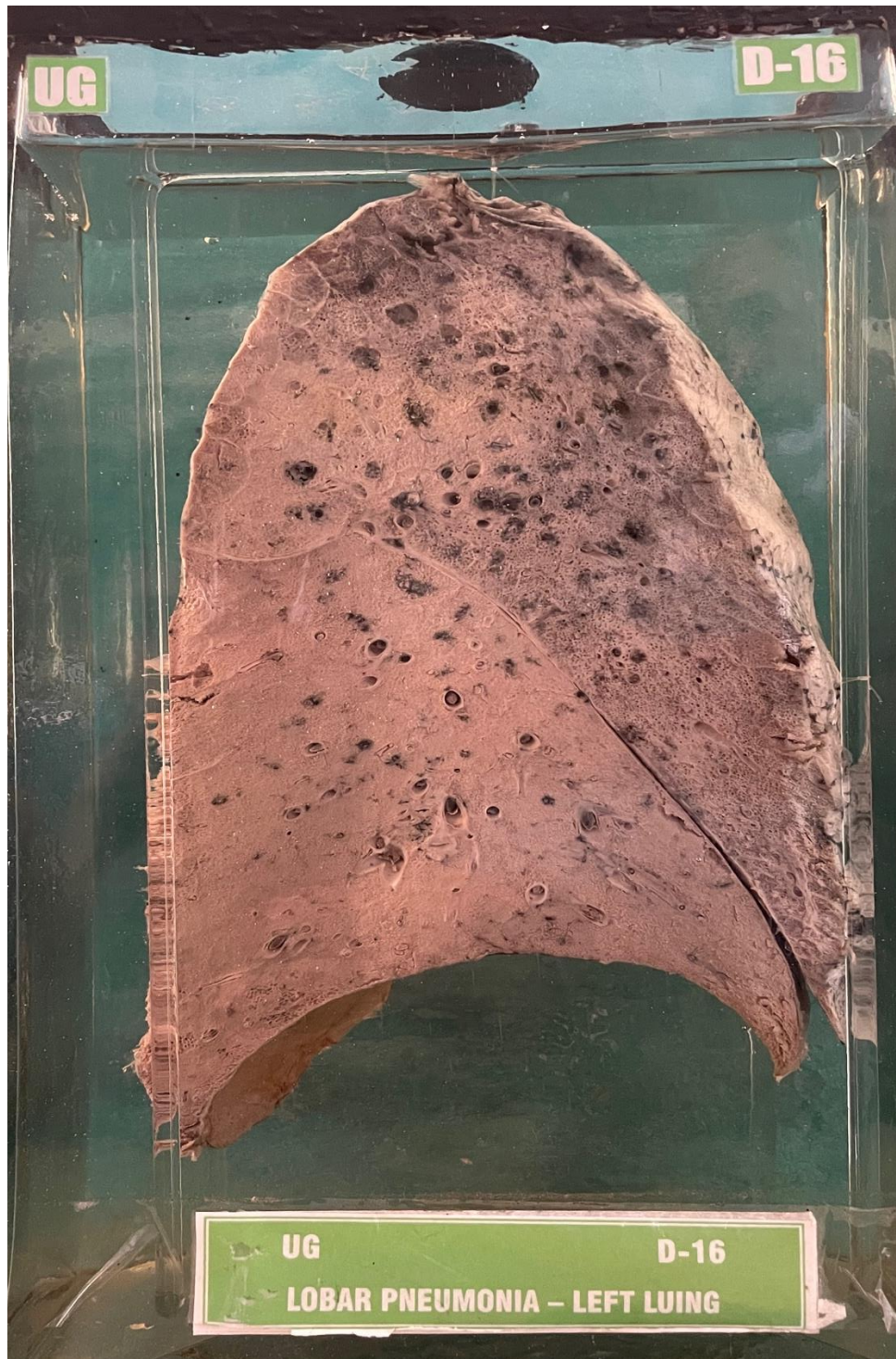


D16 – LOBAR PNEUMONIA-LEFT LUNG



- Bisected specimen of left lung.
- The pleura over the lower lobe and part of upper lobe is covered with fibrinous exudate.
- The lower lobe & part of upper lobe is consolidated and appears greyish white in colour.

Impression:- Lobar pneumonia (Grey hepatisation) - left lung.