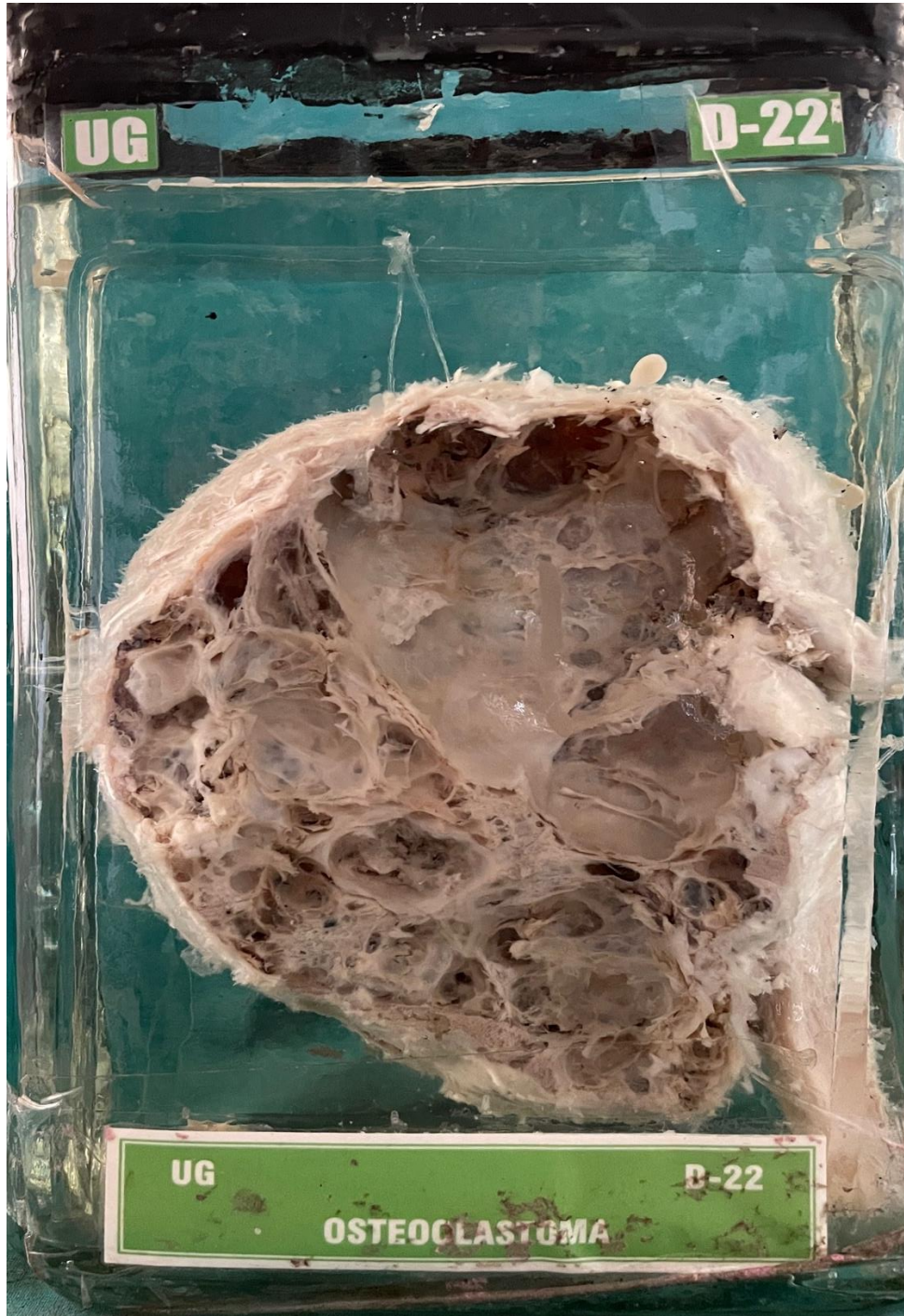


## D22 – OSTEOCLASTOMA



**OSTEOCLASTOMA**

**GROSS APPEARANCE:-** Specimen consists of a large, round tumor which has grown from the upper end of piece of bone. External surface is smooth shiny, capsulated. Capsule is thin. Cut surface shows cystic spaces of irregular sizes. Haemorrhagic and necrotic areas are present.

**DIAGNOSIS:-** Osteoclastoma.

