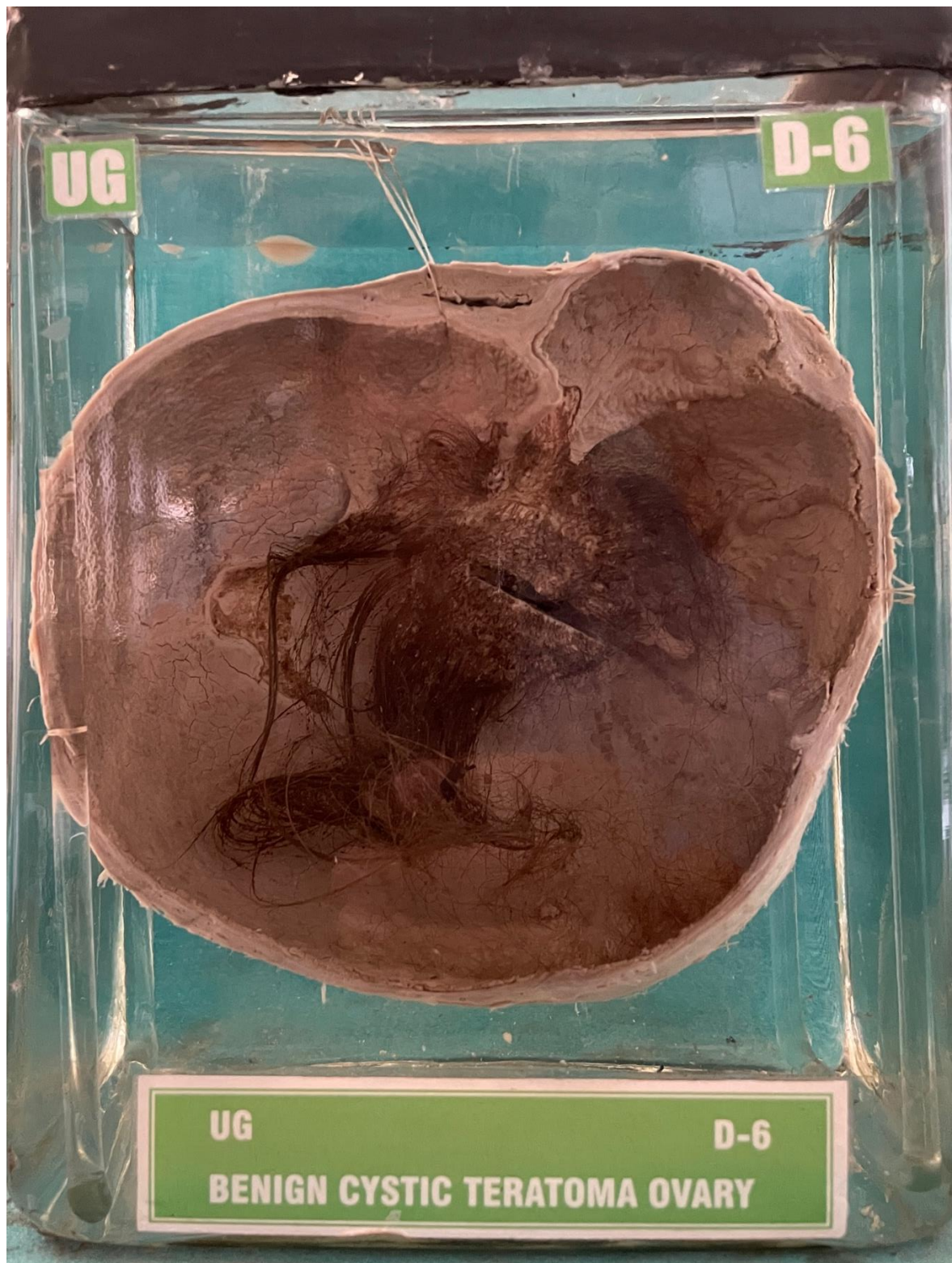

D6 – BENIGN CYSTIC TERATOMA OVARY




BENIGN - CYSTIC - TERATOMA - OVARY(DERMOID)

Patient aged 25 years, was admitted with acute complained of pain in the lower part of the abdomen.

GROSS APPEARANCE:- Specimen consists of tube alongwith ovary on one side. A large cystic, doughy mass arising from the ovary. Cut surface - The lumen of this cyst, is filled with hair and sebaceous material which is yellow white. The wall appears haemorrhagic.

HISTOPATHOLOGY:- Ectoderm is represented by skin and its appendages like hair follicles and sebaceous glands.

6A.10

BENIGN CYSTIC TERATOMA OVARY (DERMOID)

Large cystic mass
Growth seen in the lumen
lumen filled with long hairs.